

DENTAL SCANNING NOTES

FOR CONE BEAM CT SCANNERS

Version 9.1 – 2020-10-18



IMAGE DIAGNOSTIC TECHNOLOGY LTD

53 Windermere Road, Ealing, London W5 4TJ

Tel: +44 (0)20 8819 9158 UK
Tel: +353 (0)21 470 9501 Ireland
Email: info@idtscans.com
Web: www.idtscans.com

Copyright © 1992-2020 Image Diagnostic Technology Ltd.
No part of this document may be copied, photocopied, reproduced, translated to any medium or machine form without prior consent in writing from Image Diagnostic Technology Ltd.

Simplant™ is a trademark of Dentsply Sirona

TABLE OF CONTENTS

1. INTRODUCTION	3
1.1 WHAT ARE DENTAL IMPLANTS?	3
1.2 WHAT DOES IDT DO WITH THE CT SCAN?	4
1.3 WORKING WITH IDT	4
2. BEFORE YOUR FIRST SCAN	5
2.1 PRE-SCAN PREPARATION	5
2.2 INSTRUCTIONS TO THE PATIENT	5
3. POSITIONING THE PATIENT	6
3.1 PATIENT COMFORT, SUPPORT AND RESTRAINT	6
3.2 SCANNER TABLE HEIGHT	ERROR! BOOKMARK NOT DEFINED.
4. SCANNING PARALLEL TO THE REQUESTED PLANE	8
4.1 THE OCCLUSAL PLANE	9
4.2 THE LOWER BORDER OF THE MANDIBLE	10
4.3 THE HARD PALATE	10
4.4 LIMITING THE EFFECTS OF ARTEFACT CAUSED BY METALLIC RESTORATIONS	10
4.5 CHECKING THE LATERAL SCOUT VIEW	11
5. HOW MANY TRANSAXIAL SLICES TO ACQUIRE?	11
6. BEFORE LETTING THE PATIENT GO	12
6.1 CHECK FOR PATIENT MOTION	12
6.2 KEEP THE RAW DATA	ERROR! BOOKMARK NOT DEFINED.
7. SENDING THE CT DATA TO IDT	12
8. KEEPING A BACKUP COPY	12
9. THE IDT CHECKLIST	12
10. DENTAL CT FEEDBACK FORM	ERROR! BOOKMARK NOT DEFINED.

1. Introduction

These Dental CT Scanning Notes have been prepared by Image Diagnostic Technology Ltd. (IDT) to assist our customers. Please use at your own risk. While we have made every effort to ensure the information is accurate and up to date, we cannot take responsibility for any errors or omissions.

These Scanning Notes will be most useful for dental practices or imaging centres that own or operate a cone beam CT (CBCT) scanner. Separate Notes are provided for medical grade CT scanners, such as might be found in a public or private hospital.

Dental CBCT Scans are most commonly prescribed for the pre-operative assessment of patients who are candidates for the placement of dental implants. Some other applications might be: impacted third molars, supernumerary teeth, root canal assessment, and planning maxillofacial surgery. The basic requirement is to provide transaxial images of the region of interest, which in most cases will be the mandible (lower jaw), maxilla (upper jaw), or both. Occasionally, the zygoma, orbits and eyes will need to be included, but this is the exception rather than the rule.

1.1 What are dental implants?

If a patient is missing some or all of their teeth and does not wish to have a removable denture, implants can be an alternative. Implants are, in effect, titanium roots that are screwed into the bone and on which new teeth can be made by a dental laboratory. An average sized implant will be about 3.5 mm in diameter and 12 mm in length and can only be placed in bone of adequate dimensions and quality. The images that IDT generates by **reformatting** or post-processing CBCT scans demonstrate this bone in slice by slice presentations, as well as in the form of 3D views. Using these images, the surgeon can determine the ideal implant position for long-term stability, function and success.

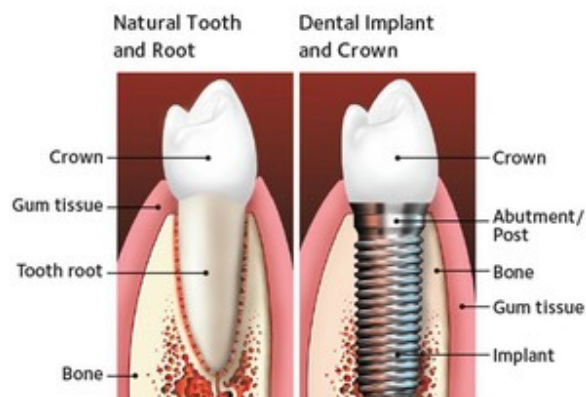


Figure 1. Natural Tooth compared with Dental Implant

1.2 What does IDT do with the CBCT scan?

The axial CT slices are post-processed using a number of software programmes including Simplant, Mimics, InVivo, Osirix and Blue Sky Plan. These convert the axials into 3D, Panoramic, and Cross-Sectional views. IDT sends all this information to the dentist or surgeon on a CD or via the internet (secure email or secure FTP). After loading the dataset onto his or her computer, the dentist or surgeon can interact with the images to evaluate different potential implant sites. 3D software such as Simplant also allows him/her to place exact replicas of implants in the bone, as he/she would during surgery. This gives an excellent overview and potential problems can readily be foreseen.

IDT can prepare datasets for a number of software packages including Simplant, Mimics, InVivo, Osirix, Blue Sky Plan, coDiagnostiX, Nobel Guide and iDent. We can also provide Radiology Reports and we have a Treatment Planning service and we can design 3D Models and Surgical Drill Guides.

As IDT uses its own reformatting software, **you do not need special software on your CBCT scanner to scan patients for IDT. The only requirement is to export the axial slices in DICOM format.**

1.3 Working with IDT

There are three ways that your dental practice or imaging centre can work with IDT:

- 1) Referring dentist books and pays for the scan plus any reformatting work online, and IDT in turn pays the imaging centre to perform the scan. This is the best scenario from IDT's point of view because we can make sure the entire process goes smoothly and maintain high standards throughout.
- 2) Referring dentist or patient pays the imaging centre for the scan plus any reformatting work and the imaging centre pays IDT for the reformatting (the exact opposite of 1). This provides "one stop shopping" for the patient but creates extra work and responsibilities for the imaging centre.
- 3) Referring dentist or patient pays the imaging centre for the scan only and pays IDT separately for the reformatting work only. This may seem like the easiest way of working, but it creates extra work for the referring dentist, as he/she must liaise and coordinate separately with both the imaging centre and with IDT. Also, it is very difficult to maintain high quality standards throughout two separate processes.

Under scenario 1, IDT can take on some of the imaging centre's administrative burden as we have put streamlined procedures in place that ensure as little paperwork as possible for the radiographers to complete. Also, we work closely with IDT Scanning Site Partners to find ways of achieving the best possible image quality at the lowest practical radiation dose.

If a dentist books a scan directly with the imaging centre instead of through IDT (scenarios 2 or 3) we will assist as much as possible but we cannot take any responsibility for the quality of the scan or delays in receiving the data.

We encourage scanning sites to send the CBCT data to us electronically via a secure service such as Virtual Private Network (VPN) or bbRad. This enables us to provide a much faster turnaround to the referring dentist. Please include the following when you send the CBCT data to IDT:

1. All axial slices
2. All ScoutViews or alignment images
3. The Patient Protocol or Dose Report screen if applicable (showing the DAP).

Please ensure that all axial slices are in DICOM format. DO NOT include any reformatted images (Sagittal or Coronal or 3D views).

Please include the Dose Area Product (DAP) because we will use it to estimate the Effective Dose (in microSv) and report these numbers back to the referring dentist.

Please do NOT process or reformat the data using your own software. Datasets that have been processed or reformatted cannot be processed further by IDT. Please send us the axial slices exactly the way they were reconstructed by the scanner.

2. Before your First Scan

Please select a high resolution, low dose protocol for your CBCT scanner. IDT can assist you in choosing a suitable protocol. Our protocols have been chosen to represent a realistic tradeoff between image quality and an appropriate radiation dose. If you change scanners, please inform IDT so that we can help you choose a protocol for your new scanner.

2.1 Pre-scan Preparation

Carry out your normal pre-scan checks to identify the patient and ensure the patient is suitable for a procedure involving medical radiation.

Ask the patient to remove any metal dentures (chrome-cobalt plates) or dentures with any metal parts (clasps). If the patient's dentures are metal-free, the patient should wear them, unless he or she was given a stent (scanning prosthesis) by the dentist to wear instead. Information regarding the stent should be on the dentist's Referral Letter. If the patient did not bring a stent but the Referral Letter indicates one should be worn, please contact the referring dentist or IDT before scanning the patient.

2.2 Instructions to the Patient

Please explain to the patient that they must stay entirely still during the scan. It is of utmost importance that the patient does not move. To prevent even the slightest movement, the mandible should be "locked" to the maxilla. If the patient has natural teeth, or a denture, or a stent, we recommend biting down on a wooden tongue depressor to keep the teeth slightly (1-2mm) apart while stabilising the mandible. The tongue depressor should be placed crossways at the back of the mouth so that the flat side touches the back (posterior) teeth on each side.

If the patient has natural teeth in both arches, placing a tongue depressor as described above is very helpful. By having the bite open a few mm (but not too much!) it will be easier for IDT to divide the teeth to see which teeth belong to which arch. This will help derive the maximum benefit from the CBCT scan.

Never use a plastic syringe to separate the teeth as it opens the bite too much.

The patient must remain **completely motionless** during the entire scanning procedure (from the prescribing scout view right through to the final axial slice). Normal breathing will not adversely affect the study, however, any motion of the head - including swallowing - can diminish the image quality, possibly to the point where the images cannot be used. The desire to swallow during the scan can be reduced by placing the tongue on the roof of the mouth.

- Tell the patient approximately how long the scan will take
- Stress the importance of keeping entirely still
- Keep in contact with the patient at all times
- Let them know when they must stay still and when they can relax.

3. Positioning the Patient

Position the patient sitting or standing in the CBCT scanner. Please make sure the patient is entirely straight and is not rotated vertically or laterally. Align the head to achieve the requested scanning plane. Usually this requires getting the occlusal plane horizontal and the Frankfurt Plane tilted upwards by about 15°.

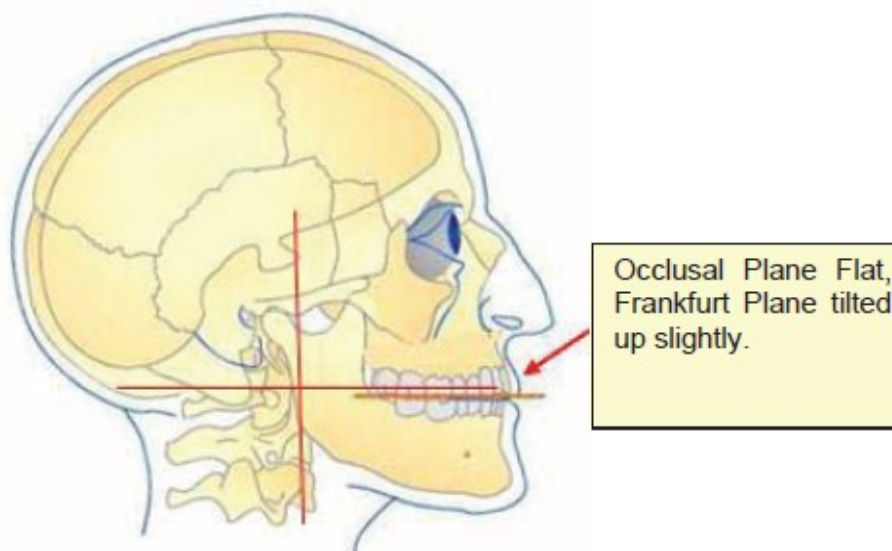


Figure 2. Patient Alignment

3.1 Patient Comfort, Support and Restraint

A relaxed and comfortable patient is less likely to move. Make the patient as comfortable as possible, and restrain them using the bite stick, chin rest or Velcro straps as applicable for your scanner. Be prepared to re-position the patient if necessary to correct the alignment.

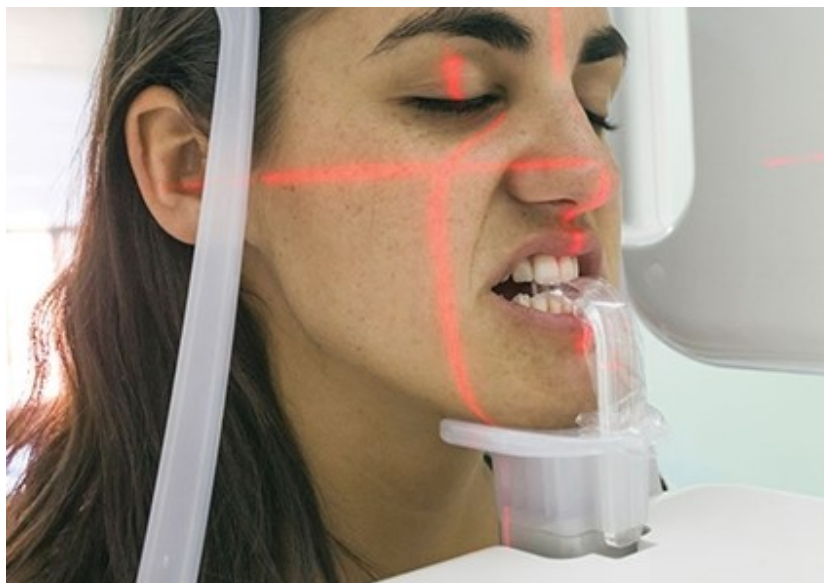

Figure 3. Patient restrained with bite stick and chin rest

3.2 Selecting the Field of View

Select the smallest scan volume (Field of View) that will capture the required anatomy, then centre the anatomy within this Field of View. Good patient positioning is very important.

Moving the patient to the side will not reduce the radiation dose. If you move the patient away from the x-ray tube in one projection, you are moving them closer to the x-ray tube in another.

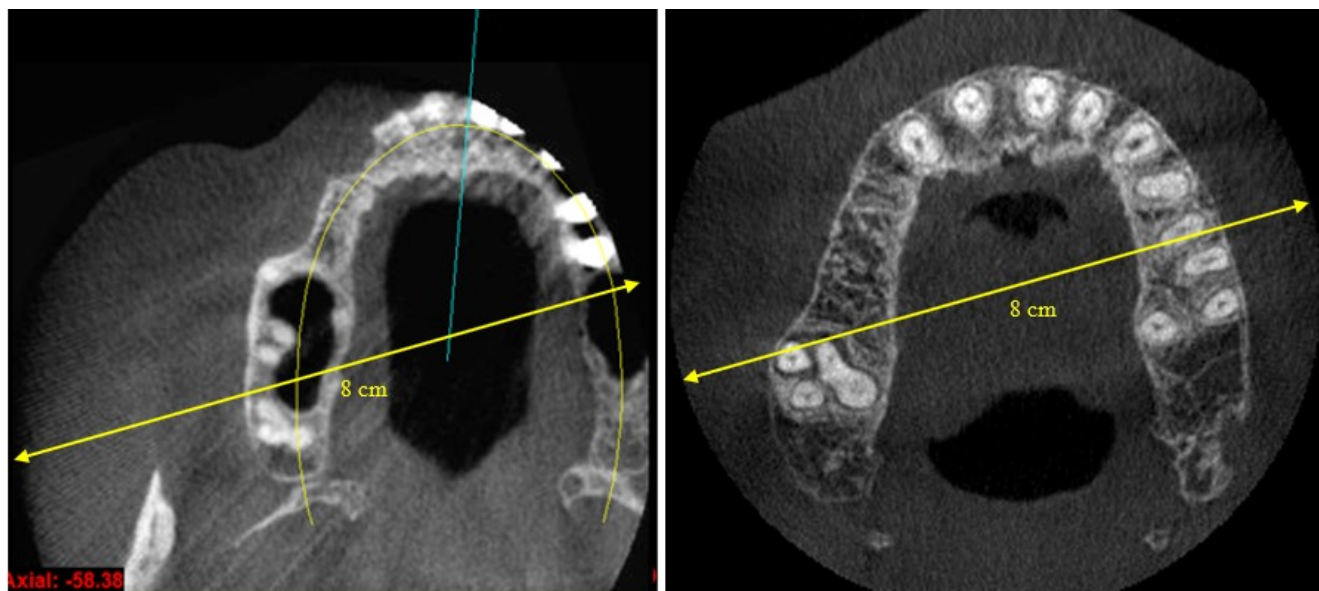


Figure 4. The Field of View is 8cm x 8cm in both images above. The DAP is the same, therefore the radiation dose is very similar. However, there is more useful clinical information in the right hand image.

3.3 Reducing the Patient Dose

The best ways to reduce the radiation dose to the patient (without losing valuable clinical information) are as follows:

- Reduce the vertical height of the scanned volume. This has the greatest beneficial effect.
- Reduce the diameter of the scanned volume. This reduces the dose, but you may lose some clinical information.
- Reduce the mAs (tube current and scan duration). This reduces the dose, but may increase the noise.

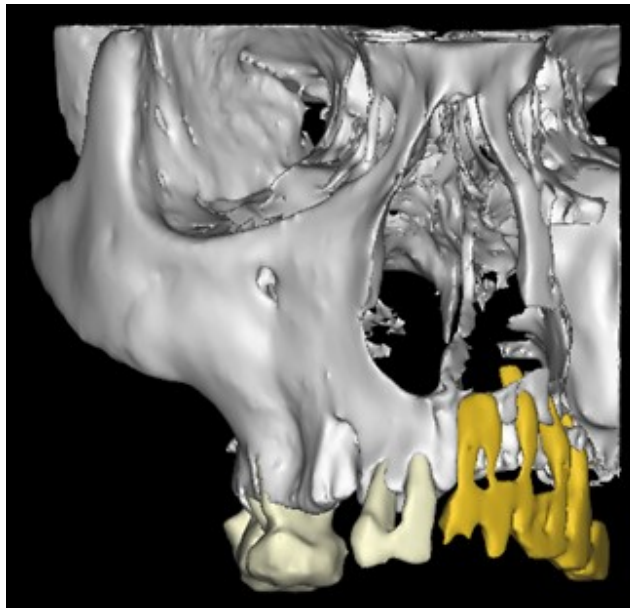


Figure 5. There is rarely any clinical benefit in scanning the orbits. It would have been better to decrease the height and increase the diameter to include all of the teeth.

4. Scanning Parallel to the Requested Plane

The dentist's Referral Letter may ask you to scan parallel to one of these three planes: the occlusal plane, the hard palate of the maxilla, or the lower border of the mandible. In some cases, the dentist might draw a line on a patient's stent to show which plane should be used. Unless the referring dentist specifies otherwise, **tilt the head so that the occlusal plane is horizontal**:

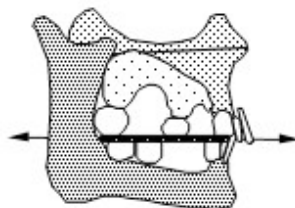


Figure 6: Scanning parallel to the occlusal plane

4.1 Parallel to the occlusal plane

Indication: Maxilla, Mandible, or both together.

UNLESS A DIFFERENT PLANE IS SPECIFIED, THIS IS THE ONE TO USE. The occlusal surface of a tooth is the biting surface, and the occlusal plane is the plane passing through the area where the maxillary and mandibular teeth come into contact when the mouth is closed. On an alignment image or scout view, this will show up as a line running from the tips of the anterior (front) teeth to the occlusal surfaces of the posterior (back) teeth.

If you are scanning both jaws, always try to scan them together whenever possible. Do not scan the patient with the mouth open, because there will be different "occlusal planes" for the maxilla and the mandible and therefore the patient will need be repositioned between maxilla and mandible scans. We recommend scanning the patient with the mouth closed, biting on a wooden tongue depressor. **Never use a plastic syringe to open the bite.**

The occlusal plane may actually be curved (curves of Monson and Spee) so you may have to imagine "straightening out" this curve and scanning parallel to the resulting imaginary plane. **If the patient is biting on a wooden tongue depressor, you can use this to indicate the occlusal plane (Figure 5):**

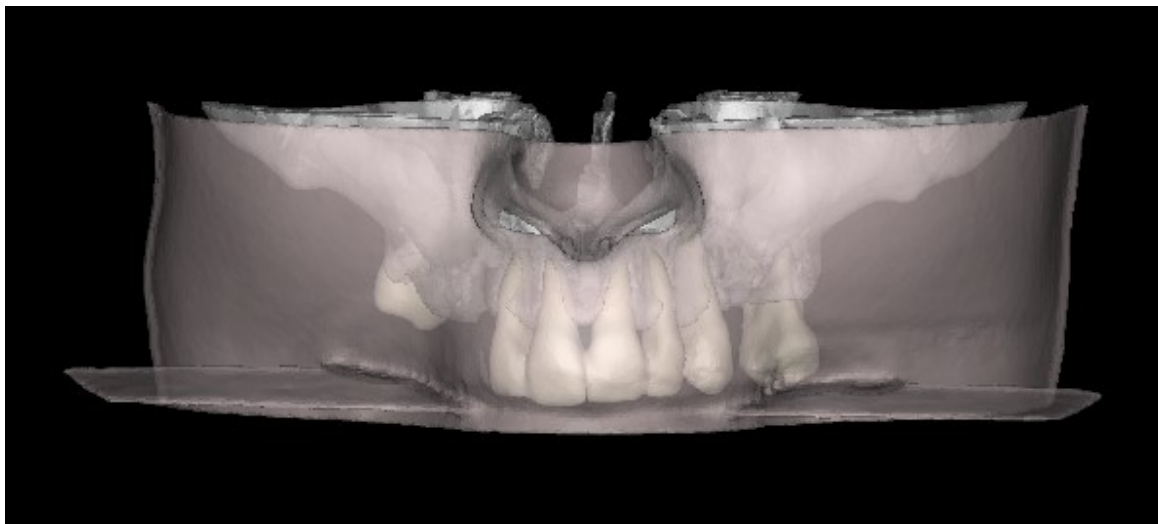


Figure 7: Patient biting on wooden tongue depressor (3D view)

Often the anterior mandibular teeth are much "higher" than the posterior teeth. This may happen because the front teeth over-erupted when there were no teeth in the opposing arch. In such cases, please ignore the anterior teeth and find the plane by only using the posterior teeth.

If in doubt, **it is always better to have the chin up a bit extra, rather than down.** This will ensure that the entire jaw is scanned, without taking unnecessary slices.

Unless the referring dentist requests otherwise, please scan all patients parallel to the occlusal plane.

4.2 Parallel to the lower border of the mandible

Indication: Mandible only

ONLY USE THIS PLANE IF EXPLICITLY REQUESTED. The lower border is the lower jaw line. If it cannot be clearly seen, it can usually be assessed by placing your thumbs along the jaw line on each side of the chin. If the referring dentist requests a scan parallel to the lower border, you need to get the jaw line horizontal. In addition, please ensure that the patient's head is straight. In other words, one side of the mandible should not be significantly lower than the other.

The lower border can be verified on a lateral scout view. Care should be taken to have both sides of the mandible at the same height, the centre of the mandible in the centre of the Field of View and the jaw line parallel to the gantry. If repositioning is needed or if the patient moved, please take a new scout view.

Under no circumstances should a maxilla be scanned parallel to the lower border of the mandible, even if this appears to be what the dentist has requested.

4.3 Parallel to the hard palate

Indication: Maxilla only

ONLY USE THIS PLANE IF EXPLICITLY REQUESTED. The hard palate is the roof of the mouth. The best way to assess this position is to check the lateral scout view. Please ensure that the patient's head is straight and centred. If repositioning is needed or if the patient moved, please take a new scout view.

4.4 Limiting the effects of artefact caused by metallic restorations

Metal restorations, such as amalgam fillings or gold crowns, will create artefact or streaks that blacken out or obscure details of bone in the scan. Patient positioning can allow artefact to be directed away from the region of interest (so it will affect the bone less than the teeth). Please use your judgement and reposition the patient if you know it will result in a better scan. Below is an illustration which you may find useful when assessing each patient and the potential for reducing artefact by repositioning.

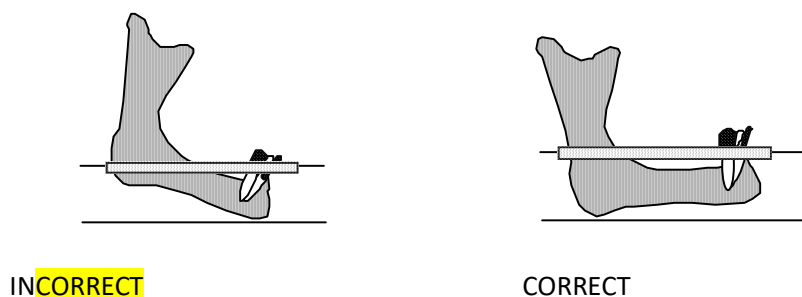


Figure 8: Adjusting the scanning plane to reduce the effects of artefact

The rectangular area in the figure above is the region that would be affected by artefact from metallic restorations in the teeth. By angling the jaw, this artefact can be directed away from the region of interest (the

bone, especially the potential implant sites). For the mandible the rule of **chin up a bit extra** usually results in a better scan.

Where artefact is present, **scanning parallel to the metal** will generally result in the minimum number of slices being affected. **Always scan the entire anatomical region requested, even if artefact will be included.** Some artefact can be removed later when IDT post-processes the images.

Consider increasing the kVp and mAs when metal is present. However, please be aware that this will increase the radiation dose.

Many CBCT scanners now have “Metal Artefact Reduction” software such as that can go a long way to reducing the effects of artefact. Sometimes this comes at the expense of reduced resolution or increased noise. If your scanner has this software, please send us 2 datasets – before and after applying the Metal Artefact Reduction algorithm – so we can decide which works best for our application.

4.5 Checking the lateral Scout View

The lateral scout view is the key to ensuring correct positioning. If the patient is seen to be incorrectly aligned after the scout view is taken, he or she must be repositioned and **another lateral scout view must be taken** to confirm the new position. IDT incorporates the scout view into the patient's dataset and therefore a correct scout view must be included in the study. Wrong scout views can be deleted as they are of no use.

5. How Many Transaxial Slices to Acquire?

On a CBCT scanner, you can control the number of transaxial slices by adjusting the vertical height of the volume to be scanned (however, not all scanners have this feature). The volume to be scanned should be the minimum needed to include the whole region of interest.

A Dental CBCT Scan of the Maxilla should include:

- about 10mm of the mandibular teeth, to indicate the occlusal relationship
- all of the bone that forms the Maxilla
- the full length of all the maxillary teeth
- the full extent of any radio-opaque markers or teeth in a stent
- at least 25 mm of sinuses above the hard palate
- all bone grafts and bone graft pins
- the full extent of all sinus grafts
- the full extent of polyps or other abnormalities
- additional regions if requested by the dentist.

If your scanner has this feature, adjust the vertical height so that the anatomy shown above is just included. An average sized maxilla study will cover 40 to 50 mm.

Check the referral form for special instructions. In special cases, the referring dentist might ask for the zygomatic arch or lower border of the orbits to be included in the study.

A Dental CBCT Scan of the Mandible should include:

- about 10mm of the maxillary teeth, to indicate the occlusal relationship
- all the bone that forms the mandible
- half of the bone that forms the ramus of the mandible
- the full length of all mandibular teeth
- the full extent of any radio-opaque markers or teeth in a stent
- all bone grafts and bone graft pins
- full extent of any abnormalities
- additional regions if requested by the dentist.

If your scanner has this feature, adjust the vertical height so that the anatomy shown above is just included. An average sized mandible study will cover 40 to 50 mm.

6. Before Letting the Patient Go**6.1 Check for Patient Motion**

Keep the patient in the scanner until all the axial scans have been reconstructed and you can view a quick sagittal and/or coronal reconstruction. This way you can verify whether or not the patient has remained motionless and the scan process has been completed properly. **If the patient has moved during the scan and you think they are capable of staying still next time, you should re-scan rather than having to call the patient back at a later date.** If in doubt, contact the referring dentist or IDT.

7. Sending the CBCT Data to IDT

Please send us the entire study, including the axial slices, scout views and any dose information. **Do not send us reformatted images (sagittals, coronals or 3Ds) that you make yourself.**

If your scanner reports (1) the scan duration in seconds, and (2) the dose-area product (DAP) in mGy.cm², please write these numbers down and include them on the paperwork or email them to IDT. Alternatively, please send a screenshot of the Dose Report or Patient Protocol screen. We will double-check these numbers and include them with the images sent to the referring dentist.

8. Keeping a Backup Copy

Please make a backup copy of the images using your local archival system (this may be your hard disk or PACS). The backup copy may be needed in case the original images get lost or corrupted. ***The back-up copy must be an exact FULL RESOLUTION copy of the images sent to IDT.***

9. The IDT Checklist

Please keep a copy of the following checklist nearby whenever doing a dental CBCT scan. It is a good "quick reference" and will ensure continued quality from your scanning site.

**THE IDT CHECKLIST
for
DENTAL CBCT SCANS**

- ☐ If there's no signed referral from the dentist – don't take the scan!
- ☐ Remove jewellery and metal dentures
- ☐ Make sure the patient is wearing the Stent if indicated on the Referral Letter
- ☐ Stabilize the jaws with a wooden tongue depressor to avoid movement
- ☐ Make sure the patient is straight and centred in the gantry
- ☐ Tilt the patient's head to the correct scanning plane
- ☐ Adjust the scanning plane to limit the effects of artefact
- ☐ Make sure the scanner settings are appropriate
- ☐ Select the smallest Field of View that covers the anatomy
- ☐ Follow any special instructions from the referring dentist
- ☐ Do not scan more than has been indicated
- ☐ Instruct the patient to keep entirely still
- ☐ Check for movement before the patient leaves
- ☐ Include Axials, ScoutViews and screen showing DAP in the images sent to IDT
- ☐ Make a backup copy on your hard disk or PACS.